

## REVIEW ARTICLE

### BIOLOGICAL RESTORATION IN DENTISTRY- A REVIEW

Harshit Singhania<sup>1</sup>, Vinisha Pandey<sup>2</sup>

<sup>1</sup>BDS final year student, Rama Dental College Kanpur, <sup>2</sup>Reader, Department of Conservative Dentistry and Endodontics, Institute of Dental Studies and Technology (IDST), Modinagar, UP, India

#### ABSTRACT:

Coronal fracture by trauma is the most frequent type of dental injury in the permanent teeth. Therefore re-attachment of coronal fragments to the remaining tooth using minimally invasive techniques i.e. using dental fragments & adhesive materials as well as composite build up can provide high fracture resistance & aesthetics to restored tooth which is known as BIOLOGICAL RESTORATION.

Key words: Biological restoration, minimally invasive dentistry.

Corresponding author: Dr. Harshit Singhania, BDS final year student, Rama Dental College Kanpur

This article may be cited as: Singhania H, Pandey V. Biological Restoration in Dentistry- A Review. Int J Res Health Allied Sci 2016;2(2):11-12.

#### INTRODUCTION

Coronal fracture by trauma is the most frequent type of dental injury in permanent dentition. Recent studies show that this injury affects upto 25% of patients (Children & teenagers). Most affected teeth are upper incisors due to anterior position & protrusion caused by eruptive process.

In past, fractured teeth were restored using acrylic resin/ complex ceramic restorations associated with metals. These restorations did not promote adequate long term aesthetics & also require significant tooth reduction during preparation.

Chosack & Eideman, 1964 were first to report it.

The expression "biological restoration" was coined in 1991 by Santos and Bianchi.

Furthermore, this technique can be less time consuming & provide more predictable long term appearance.

Improvement of hydrophilic adhesives combined with the acid etching technique possible with no additional preparation of the fracture site.

Even considering the proposed advantages of these techniques & their widespread use, the majority of these design features are selected empirically & little is known about their influence in long term success of restoration.

#### TECHNIQUES:

##### Types of biological restoration:

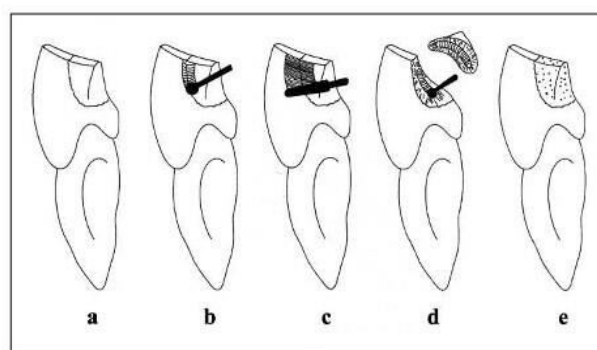
**Autogenous Bonding:** When the fractured fragment of the patient's own tooth is reattached, it is referred to as autogenous bonding.

**Homogenous Bonding:** When the patient doesn't present with the fractured fragment or its use is not

recommended, donated extracted teeth (homogenous bonding) can be used for re-attachment procedure.

- Selection of extracted tooth from tooth bank by shade matching.
- Silicon impression of fractured tooth.
- Sterilized by immersing in 0.9 N NaOH for 2 hours and then autoclaving at 121°C for 15 minutes.
- Cast of fractured tooth
- Adjustment of Segment on cast
- Acid etching of the fractured tooth was carried out for 15 seconds using 37% phosphoric acid & Bonding agent was subsequently applied
- The fragment was held in its proper position and the adhesive resin was light cured for 20 seconds.
- Finishing and Polishing was performed using diamond burs and sandpaper disks.

#### OTHER TECHNIQUES:



- (a) Bonded only
- (b) Chamfer
- (c) Overcontour
- (d) Internal Groove
- (e) Composite build up

### INDICATIONS

Insufficient tooth surface to retain amalgam/composite.  
Rampant caries  
Fractured Tooth

### CONTRAINDICATIONS

Bovine Teeth  
Pulpal Involvement  
Apical Periodontitis

### ADVANTAGES

Conservative Technique  
Immediate restorative procedure  
It provides total aesthetic recovery because of the natural tooth contour, colour, translucency, and surface texture provided by the reattached fragment. It also provides colour stability over time and the rate of wear is similar to other natural teeth.

### DISADVANTAGE

Non acceptance by patient.

### DISCUSSION

Several authors advocate placement of bevel around the fracture site to increase fragment retention & longevity. Its placement alters the enamel prisms orientation allowing a more effective enamel acid etching.

Placement of an internal groove may provide higher aesthetic durability as well as excellent fracture strength of the restoration.

Resin composite build up is the most popular way to restore a fractured tooth when fragment is not available.

Survival time is similar in both treatment reattachment of tooth & composite build up according to Andreasen & others 1995.

### CONCLUSION

According to methodology used, it was concluded that overcontour technique, the placement of an internal groove & composite build up technique provided fracture strength similar to those in sound

teeth. Bonding with no additional preparation & placement of chamfer are not indicated due to low fracture strength obtained.

Fracture of anterior teeth by trauma is a common problem in children & teenagers. Complex metal ceramic crowns with a considerable loss of remaining sound structure are no longer necessary due to amelioration of adhesive techniques such as composite restoration & reattachment technique.

**SUMMARY:** This paper gives an overview of the concepts of minimal intervention dentistry & describes suggested technique for a minimally invasive operative approach. The concept of minimal intervention dentistry has evolved as a consequence of development of adhesive restorative materials. Treatment of maxillary anterior can be now effortlessly completed within single appointment, if original tooth fragment is retained following fracture. Natural tooth structure can be reattached using adhesive protocol to ensure strength, translucency & colour stability known as **Biological Restoration.**

### REFERENCES

1. Mittal & Swain, Dentistry 2014, 4:7
2. Operative Dentistry 2001, 26,287-294
3. Reis & others
4. Andreasen FM (1991) Reinforcement of bonded crown fractured incisors with porcelain veneers Endodontics & Dental Traumatology 7(2)78-83
5. Burke FJ(1991)Reattachment of fractured central incisors tooth fragment British Dental Journal 170(6)223-225
6. Santos J& Bianchi J (1991)Restoration or severely damaged teeth with resin bonding systems: Case reports Quintessence International 22(8)611-615
7. Farik B(1998a)adhesive bonding of fractured anterior teeth Endodontics & Dental Traumatology 14(3) 119-123
8. Walker M (1996) fractured tooth fragment reattachment General dentistry 44(5)434-436

Source of support: Nil

Conflict of interest: None declared

This work is licensed under CC BY: **Creative Commons Attribution 3.0 License.**